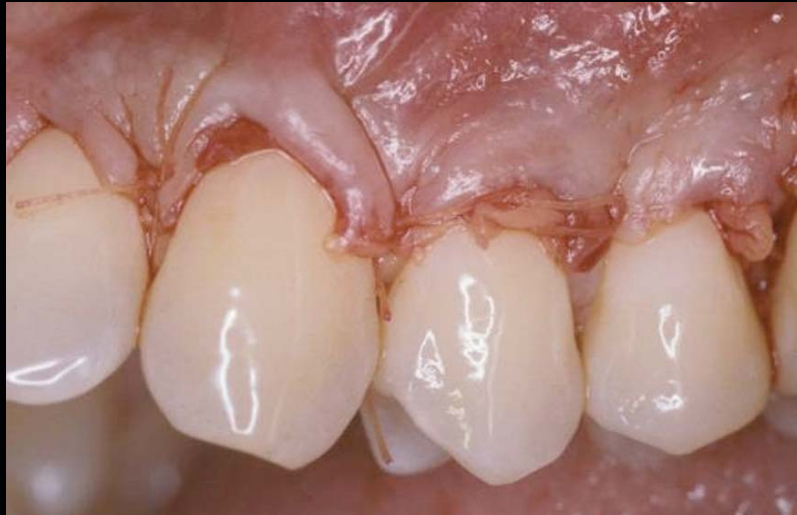

CURRENT TRENDS IN GINGIVAL RECESSION COVERAGE—PART II: ENAMEL MATRIX DERIVATIVE AND PLATELET-RICH PLASMA

André P. Saadoun, DDS, MS*



The recession of the gingiva is increasingly becoming a prominent condition in the oral health of many patients and should be treated at its earliest detection. Part I of this discussion reviewed the multifactorial etiology and decision modality; a treatment option was demonstrated for gingival recession using the tunneling technique. This concluding part of the discussion highlights two clinical cases using alternative approaches. The correction of Class I and II gingival recessions are presented as a means of minimizing surgical trauma and achieving predictable aesthetic results.

Learning Objectives:

This article describes the nature and causes of gingival recessions and presents several treatment therapies aimed at correcting it. Upon reading this article, the reader should:

- Understand why gingival recession is a concern both functionally and aesthetically for the soft and hard tissue.
- Become familiar with the causes of gingival recession and two alternate treatment options available to correct it.

Key Words: gingival recession, coronally positioned flap, tunnelling procedure, platelet-rich plasma, enamel matrix derivative, surgical trauma

*Private practice, Paris, France.

André P. Saadoun, DDS, MS, 29, rue François 1er, 75008 Paris, France
Tel: +33-1-47-27-1757 • E-mail: andre.p.saadoun@wanadoo.fr

The surgical techniques used for root coverage are based on tissue displacement, whether by translation (ie, pedicle flap procedure) or by grafting (ie, free gingival or connective tissue graft [CTG] procedures). Modifications of these two basic techniques have been developed, proposed, and combined with membranes or tissue-engineered material.

The goals of these techniques are the thickening of the gingiva, achieving perfect chromatic integration, and optimal aesthetics. The following conclusions can be drawn from recent analysis of 20 papers on the treatment of Class I and II localized gingival recession:

- Better results were achieved by using the CTG than with guided tissue regeneration (GTR);
- There is no difference between resorbable and nonresorbable membranes; and
- A closer contact between the receiving bed and the covering tissues is obtained.

There was no difference in attachment gain. The CTG was statistically superior to GTR, even if the GTR and the coronally positioned flap could be used together. The chemical treatment of the root surface does not have any influence. The subepithelial¹ is currently seen as the most predictable technique available to achieve root coverage, while maintaining high aesthetics. The disadvantages of these procedures include the need for an additional donor site, surgical procedure, and its technical difficulty. Additionally, these procedures often heal primarily with long junctional epithelium with limited connective tissue attachment. In addition, the advantages of the CTG technique include less postoperative discomfort, fewer visits, and a more aesthetically pleasing result than free gingival graft and GTR with membrane.^{2,3}

The application of the technique, however, is limited by the donor tissue thickness or the greater palatine neurovascular complex. Furthermore, proximity to the cemento-enamel junction of the bulky tissue contour resulting from the technique yields poorer aesthetics, and may require a second surgical procedure (ie, dermabrasion) to achieve better aesthetics.⁴

Enamel Matrix Derivative (EMD)

Enamel matrix derivative has been shown to promote cementogenesis and bone formation as well as new attachment.^{5,6} It has been shown that EMD possesses the potential to stimulate the formation of new connective tissue, new bone, new periodontal ligament, and cementum.^{5,6} Cumulative evidence indicates EMD's ability to increase proliferation, migration, adhesion, and differentiation of cells responsible for tissue healing in vivo.⁷ Several studies have shown that EMD may not only enhance periodontal regeneration, but may also

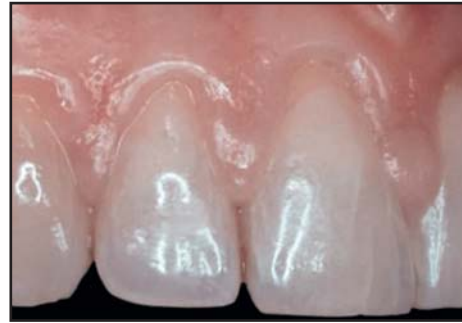

Figure 1. Case 1. Class I recessions on the incisor teeth. The central incisor papilla is compressed due to lingual orthodontic therapy.

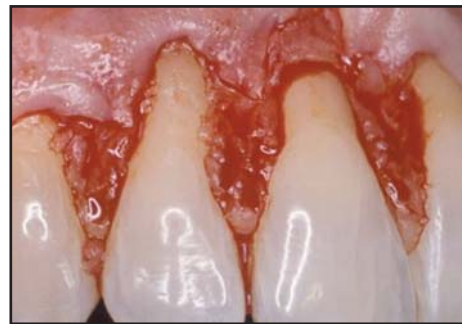

Figure 2. A partial-thickness flap is elevated via gingivoplasty of the papillae peaks.

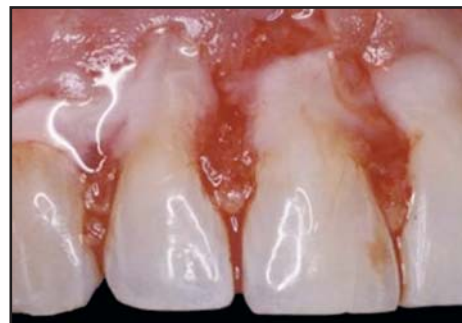

Figure 3. After root planing, the acid gel is applied on the root surfaces.

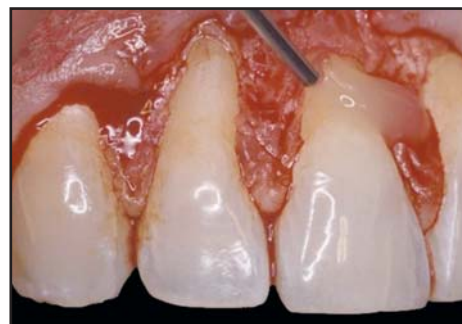

Figure 4. Application of Emdogain (Straumann, Andover, MA) on the exposed etched and dried roots.

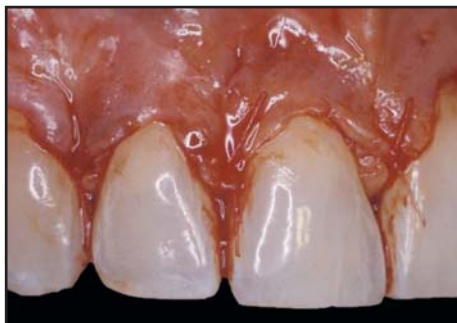

Figure 5. The flap is advanced coronally over the gel and sutured.

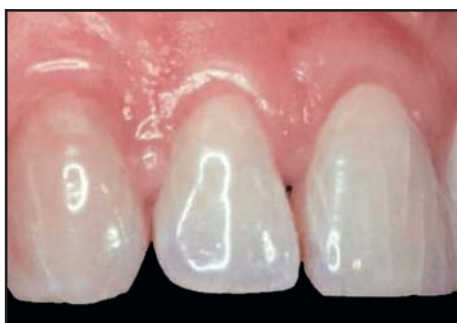

Figure 6. Aesthetic results 6 months following surgery. Note the root coverage keratinized gingiva up to the CEJs and gingival thickness.

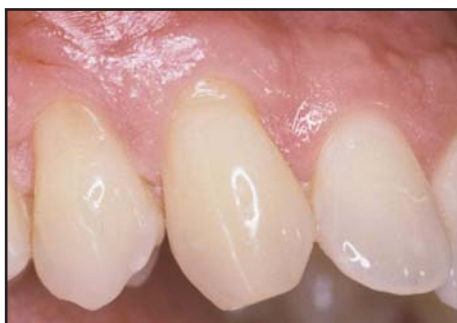

Figure 7. Case 2. Class I recession on the right canine and the first bicuspid.

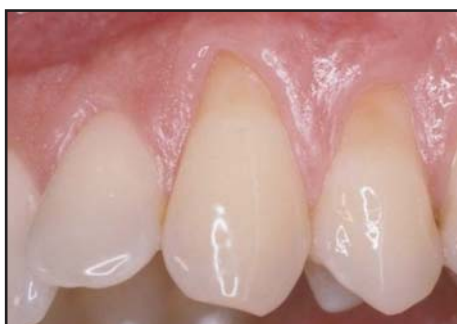

Figure 8. Class I recession on the left canine and the first bicuspid.

influence soft tissue healing by migration of periodontal ligament cells and gingival fibroblasts to the root surface⁸ by gingival fibroblast stimulation.⁹

The efficacy of using EMD in root coverage procedures has been shown to produce successful results and a gain of keratinized tissue after four months.¹⁰⁻¹³ The application of EMD during collagen membrane GTR-based root coverage procedures did not provide additional benefits to the final clinical outcome.¹⁴

Case Presentation

A 45-year-old female with a very thin biotype had just completed lingual orthodontic treatment and complained that the central incisors, right lateral incisor, and canines were hypersensitive to hot and cold temperatures. She also presented with Class I gingival recession (Figure 1). Due to the depth of the vestibule and an optimal quantity and quality of keratinized tissue above the recession, it was decided to use the Emdogain (Straumann, Basel, Andover, MA) application in this case.

A bevelled, scalloped incision was made into the adjacent interdental papillae, located 2 mm to 3 mm from the tip of the papillae, and was combined with a marginal sulcular incision. The mesiodistal line angle of the most mesial and distal teeth were involved in this incision. A full-thickness flap was then reflected beyond the mucogingival junction and at least 5 mm apical to the most apical margin of the bony dehiscence. A partial-thickness flap was made by sharp dissection to permit flexibility in the coronal direction, and a gingivoplasty was performed on the remaining papillae tips (Figure 2). The flap was raised and the root surfaces carefully planed and acid etched before the roots were thoroughly rinsed with water and dried (Figure 3).

The EMD gel was then applied on the root surface and the flap was advanced coronally and carefully sutured with a 5-0 vicryl suture totally covering the gingival recessions (Figures 4 and 5). The blood clot and the gel in excess were not rinsed out before releasing the patient in order to prevent disturbing the bonding between the root, gel, and flap.

The patient presented with postoperative edema for a few days because of the deep partial dissection. Her hypersensitivity disappeared after two weeks. Six months later, she presented with harmonious contour of the thicker keratinized gingiva and no discrepancy in the color of the margin (Figure 6) (Table 1).

Platelet-Rich Fibrin (PRF) Membrane

Platelet concentrate (PC) is an enhanced concentration of platelets processed from platelet-rich plasma (PRP).

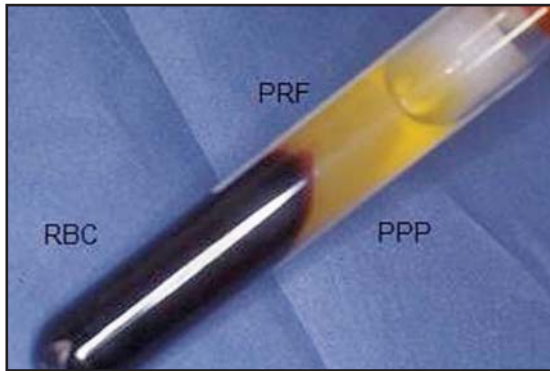


Figure 9. Centrifuged vial of blood. From bottom to top: red blood cells, PRF, and platelet-poor plasma.

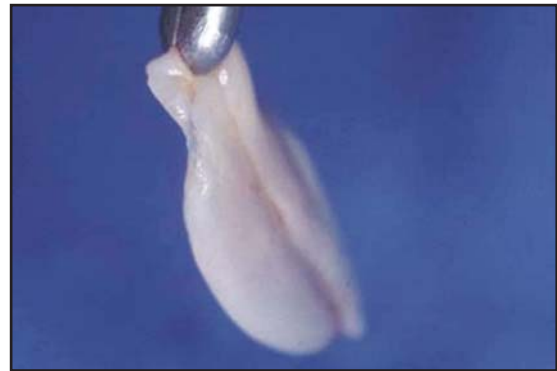

Figure 10. The PRF gel is separated from the other layers and placed on special gauze prior to compression. Clinical aspects of three overlapped PRF membranes.

Platelet-Rich Fibrin (PRF) affects cell biology activities on both the genetic and cellular levels.^{15,16} The action of growth factors present in PRP is more complex (ie, they interact and regulate each other's effects). Platelet-derived growth factor (PDGF)-AA and (PDGF)-BB were both major mitogens for human periodontal ligament cells and transforming growth factor. (TGF)- β played a significant role as a regulator of the mitogenic responses and the immune response.^{16,17}

The fibrin clot derived from PRP was able to stimulate Type I collagen synthesis. Since the platelet concentrate has a higher number of platelets per millimeter, it should contain a higher concentration of growth

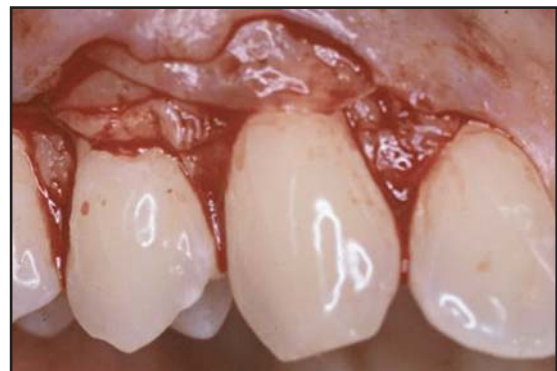

Figure 11. The membranes are placed on the right vascularized recipient bed and over the recession.

Table 1

Enamel Matrix Derivative	
Advantages	Disadvantages
Only one surgical site	Increased expense
Perfect adaptation on the recipient site	Sensitive mucogingival surgery
High vascularization of the advanced flap	
Briefer surgery	
Less postoperative edema than with connective tissue (ie, subepithelial CTG)	
Increased thickness of keratinized gingiva	
Harmonious gingival color and texture	
Highly aesthetic result	

factors to accelerate or enhance regeneration.¹⁷ When using the PRF membrane without a coagulant, the need for a donor site will be eliminated, making this technique less invasive. There was less postsurgical discomfort, more rapid soft tissue healing with less edema compared to the tunnel CTG and EMD techniques, and a relatively unlimited source of graft material.

Case Presentation

A 35-year-old male presented with asymmetrical recession on his maxillary canines and first premolars bilaterally (Figures 7 and 8). The decision was made to use the PRF membrane to treat this Class I recession.

Prior to surgery, six bottles of anticoagulant-free blood were drawn from the patient and placed for 12 minutes of centrifugation (Figure 9).¹⁸ Thereafter, a bevelled, scalloped incision was made into the adjacent interdental papillae located 2 mm to 3 mm from the tip of the papillae and was combined with a marginal sulcular incision. The mesiodistal line angles of the most mesial and distal teeth were involved in this incision. A

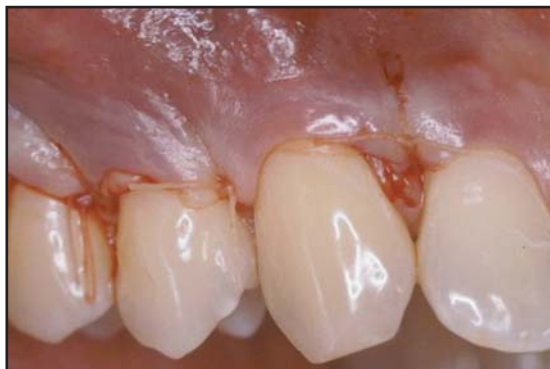

Figure 12. The membranes are placed on the left vascularized recipient bed and over the recession.

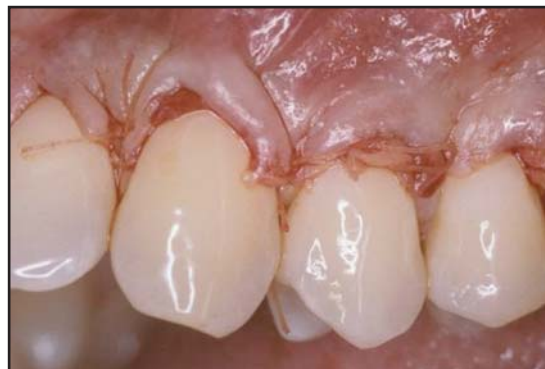

Figure 14. The left flap is advanced coronally without tension covering the PRF membranes.

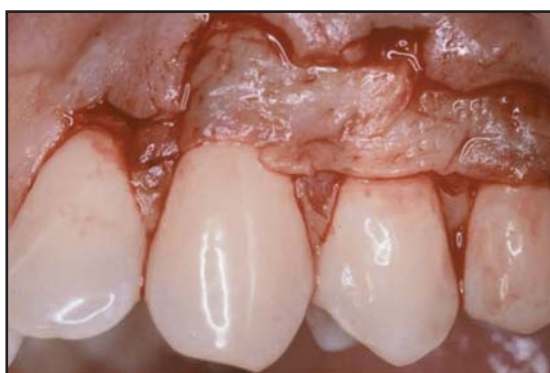

Figure 13. The right flap is advanced coronally without tension covering the PRF membranes.

full-thickness flap was then reflected beyond the mucogingival junction and at least 5 mm apical to the most apical margin of the bony dehiscence. A partial-thickness flap was further created by sharp dissection to permit flexibility in the coronal direction.

The PRF gel was compressed in order to obtain six membranes, which were then divided in two to obtain three overlapping membranes (Figure 10).¹⁹ They were placed on the recipient bed and over the recession (Figures 11 and 12). The primary flap was then advanced coronally over the membranes and sutured delicately (Figures 13 and 14). The patient presented postoperatively with minimal postoperative edema and pain. The healing was uneventful and the aesthetic results on both sides were excellent (Figures 15 and 16) (Table 2).

Gingival Recession and Implants

The increased use and reliability of implantology begs the question: Why undertake a costly, long-term maintenance program to save teeth, when they could simply be extracted and replaced by implants without

periodontium?²⁰ For the majority of patients, the conservation of teeth is a psychological necessity. Furthermore, implants cannot be placed in zones of periodontitis without risking contamination; periodontal treatment is thus imperative. Periodontal therapy enables the practitioner to stabilize lesions and analyze the long-term motivation of the patient, since implants demand the same rigorous plaque control as natural teeth.

The peri-implant bone and mucogingival tissues are almost the same as the periodontium tissues, and they react the same way to the absence of hygiene, to plaque accumulation, and to occlusal overload. Understanding the biological, microbiological, and immunological mechanisms that control the periodontium make it easier to manage peri-implant problems.

Table 2

Platelet-Rich Plasma	
Advantages	Disadvantages
One surgical site	Increased cost
High vascularization of the advanced flap	Sensitive mucogingival surgery
Excellent adaptation on the recipient site	Drawing of blood from the patient
Lengthy surgery	
Minimal postoperative edema and discomfort	
Harmonious gingival color and texture	
Normal thickness of keratinized gingiva	
Highly aesthetic result	

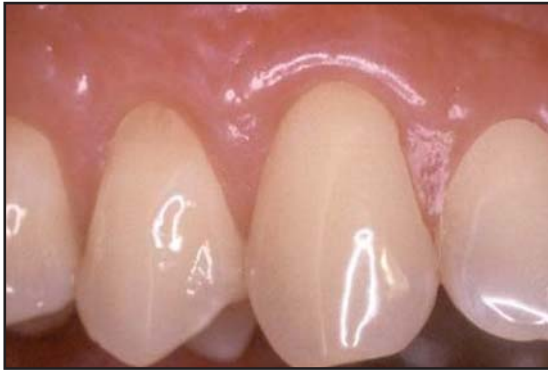

Figure 15. Increased keratinized gingiva can be seen in the right maxillary one year postoperatively.

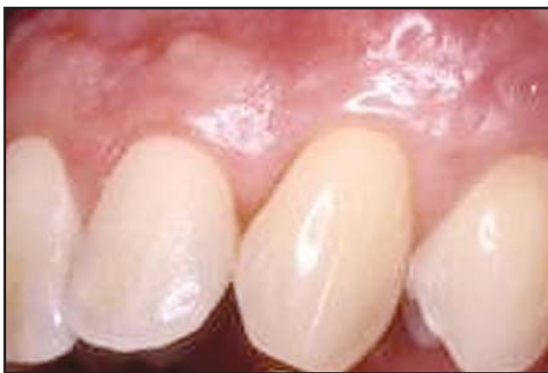

Figure 16. Color harmony, with a probing depth of less than 1 mm, can be seen in the left maxillary after 1 year .

Achieving an optimal aesthetic result is difficult to obtain with implants in the anterior aesthetic zone. The gingiva, particularly if it is narrow in a thin-scalloped biotype, inevitably retracts 6 months after the abutment connection and restoration, due to the reformation of the biologic width. The challenge, then, becomes properly treating recession (ie, bone and gingiva) around an implant.

All peri-implant mucogingival techniques come from periodontal surgery. Peri-implant recession can be prevented in overbuilding the site by adding bone on the buccal cortical plate before, or in conjunction with, implant placement. Additionally, CTG can be added in conjunction with implant placement during the integration phase and at the abutment connection/temporary restoration. A pedicle flap combined with a CTG can also serve as a treatment alternative in a thick, flat biotype, where there is sufficient tissue width and thickness on the teeth adjacent to the site of peri-implant recession. The management of the abutment placement and the implant restoration are also part of preventing the occurrence of peri-implant gingival recession.

Conclusion

The surgical technique of choice depends on several factors as outlined in this two-part article. The clinician should choose from among the different surgical protocols available, selecting the least traumatic to the patient. All three approaches described herein can effectively treat deep and shallow Class I or II buccal recessions. The PRF technique, however, may yield a better aesthetic appearance, is less invasive, and shows great promise. Further investigation should be conducted to verify the predictability and potential of this new approach.

Acknowledgment

The author declares no financial interest in any of the products cited herein.

References

1. Nelson SW. The subpedicle connective tissue graft. A bilaminar reconstructive procedure for the coverage of denuded root surfaces. *J Periodontol* 1987;58(2):95-102.
2. Zabalegui I, Sicilia A, Cambra J, et al. Treatment of multiple adjacent gingival recessions with the tunnel subepithelial connective tissue graft: A clinical report. *Int J Periodont Rest Dent* 1999;19(2):199-206.
3. Rocuzzo M, Bunino M, Needleman I, Sanz M. Periodontal plastic surgery for treatment of localized gingival recessions: A systematic review. *J Clin Periodontol* 2002;29(3):178-196.
4. Grupe HE, Warren RF Jr. Repair of gingival defects by a sliding flap operation. *J Periodontol* 1956;27(2):92-99.
5. Wennström JL, Zucchelli G. Increased gingival dimensions. A significant factor for successful outcome of root coverage procedures? A 2-year prospective clinical study. *J Clin Periodontol* 1999;23(8):770-777.
6. Harris RJ. A comparative study of root coverage obtained with guided tissue regeneration utilizing a bioabsorbable membrane versus the connective tissue with partial-thickness double pedicle graft. *J Periodontol* 1997;68(8):779-790.
7. Rosetti EP, Marcantonio RA, Rossa C Jr, et al. Treatment of gingival recession: Comparative study between subepithelial connective tissue graft and guided tissue regeneration. *J Periodontol* 2000;71(9):1441-1447.
8. Hammarstrom L. The role of enamel matrix proteins in the development of cementum and periodontal tissues. *Ciba Found Symp* 1997;205:246-260.
9. Zetterstrom O, Andersson C, Eriksson L, et al. Clinical safety of enamel matrix derivative (EMDOGAIN) in the treatment of periodontal defects. *J Clin Periodontol* 1997;24(9):697-704.
10. Sculean A, Chiantella GC, Windisch P, Donos N. Clinical and histologic evaluation of human intrabony defects treated with an enamel matrix protein derivative (Emdogain). *Int J Periodont Rest Dent* 2000;20(4):374-381.
11. Mellonig JT. Enamel matrix derivative for periodontal reconstructive surgery: Technique and clinical and histologic case report. *Int J Periodont Rest Dent* 1999;19(1):8-19.
12. Carnio J, Camargo PM, Kenney EB, Schenk RK. Histological evaluation of 4 cases of root coverage following a connective tissue graft combined with an enamel matrix derivative preparation. *J Periodontol* 2002;73(12):1534-1543.
13. Wennström JL, Lindhe J. Some effects of enamel matrix proteins on wound healing in the dento-gingival region. *J Clin Periodontol* 2002;29(1):9-14.
14. Hoang AM, Oates TV, Cochran DL. In vitro wound healing responses to enamel matrix derivative. *J Periodontol* 2000;71(8):1210-1277.
15. Ito K, Ito K, Owa M. Connective tissue grafting for root coverage in multiple Class III gingival recessions with enamel matrix derivative: A case report. *Pract Periodont Aesthet Dent* 2000;12(5):441-446.
16. Ito K, Akutagawa H. Periosteal connective tissue grafting or root coverage with enamel matrix derivative: A case report. *J Esthet Restor Dent* 2001;13(3):172-178.
17. Kawase T, Okuda K, Wolf LF, Yoshie H. Platelet-rich plasma-derived fibrin clot formation stimulates collagen synthesis in periodontal ligament and osteoblastic cells in vitro. *J Periodontol* 2003;74(6):858-864.
18. Choukroun J, Dohan D. PRF, biomatériaux de potentialisation de la cicatrisation. SYFAC congress Nice 2005 May 28.
19. Morioussef G. PRF et chirurgie muco-gingivale. *Implantologie* 2004;2:69-75.
20. Strayhorn CL, Garrett JS, Dunn RL, et al. Growth factors regulate expression of osteoblast-associated genes. *J Periodontol* 1999;70(11):1345-1354.

CONTINUING EDUCATION (CE) EXERCISE No. X



To submit your CE Exercise answers, please use the answer sheet found within the CE Editorial Section of this issue and complete as follows: 1) Identify the article; 2) Place an X in the appropriate box for each question of each exercise; 3) Clip answer sheet from the page and mail it to the CE Department at Montage Media Corporation. For further instructions, please refer to the CE Editorial Section.

The 10 multiple-choice questions for this Continuing Education (CE) exercise are based on the article "Current trends in gingival recession coverage—Part II: Enamel matrix derivative and platelet-rich plasma," by André P. Saadoun, DDS, MS. This article is on Pages 000-000.

- 1. One goal of EMD and PRP is the thickening of the gingiva. Another goal is achieving perfect chromatic integration.**
 - a. Only the first statement is true.
 - b. Only the second statement is true.
 - c. Neither statement is true.
 - d. Both statements are true.
- 2. What clinical parameters do the tunnelling and coronally repositioned flaps using EMD have in common?**
 - a. Postoperative edema.
 - b. High partial dissection.
 - c. Shorter time of the procedures.
 - d. All of the above.
- 3. The subepithelial CTG procedure is the most predictable technique available to achieve root coverage. It can be performed without an additional donor site.**
 - a. Only the first statement is true.
 - b. Only the second statement is true.
 - c. Neither statement is true.
 - d. Both statements are true.
- 4. Which of the following is NOT a characteristic of the PRP procedure?**
 - a. Excellent adaptation.
 - b. Harmonious gingival.
 - c. Multiple surgical sites.
 - d. Minimal postoperative edema.
- 5. The techniques discussed in this paper can be used to correct which of the following recession classes?**
 - a. Classes I and II.
 - b. Classes I through III.
 - c. Classes I and III.
 - d. Classes II and III.
- 6. Disadvantages to the EMD procedure include which of the following?**
 - a. Increased cost.
 - b. Sensitive mucogingival surgery.
 - c. Both of the above.
 - d. Neither of the above.
- 7. The PRF membrane was prepared from the patient's blood without an anticoagulant. Which of the following biological reaction does not apply to the PRF?**
 - a. It stimulates type I collagen synthesis.
 - b. It accelerates and enhances periodontal regeneration.
 - c. It makes the procedure much longer and more painful.
 - d. It induces minimum edema postoperatively.
- 8. Which of the following describes the potential of EMD?**
 - a. Formation of new connective tissue.
 - b. Formation of new bone.
 - c. Formation of new periodontal ligament.
 - d. All of the above.
- 9. When using the PRF membrane without a coagulant, which of the following is eliminated?**
 - a. Donor site.
 - b. Rapid tissue healing.
 - c. Patient comfort.
 - d. Both b and c.
- 10. Why can implants NOT be placed in zones of periodontitis?**
 - a. Poor fit.
 - b. Improper bone level.
 - c. The risk of contamination.
 - d. None of the above.